



A rare case of primary tuberculosis complex in the abdomen

Mira Delima Asikin^{1*}, Dhessy Susanto²



DOI : 10.36216/jpd.v7i1.212

Cutaneous tuberculosis (CTB) is the rarest form of tuberculosis (TB). CTB cases account for less than 1% of all TB cases and about 15% of all extrapulmonary tuberculosis (EPTB) cases. CTB is rare even in communities where it is endemic. CTB has a variety of manifestations and can appear similar to other disease processes. Therefore, many clinicians have difficulty recognizing CTB because CTB is known to be a great imitator. We present an unusual case of CTB which happened to be a primary tuberculous complex (PTC) manifested as an ulcerated abdomen in a 33-year-old woman. Previous medications received showed no improvement and referred to the hospital for further treatment. Histopathology of the skin lesion showed fibrous connective tissue that contained granulomas composed by epithelioid histiocytes, lymphocytes, plasma cells, and multinucleated giant cells. Patients were given therapy in the form of a fixed-dose combination of antituberculosis drugs (fixed-dose combination/FDC) and vitamin B6. Despite being rare, PTC is important to consider in patients with suggestive clinical pictures of the infection.

Keywords: tuberculosis, cutaneous tuberculosis, ulcerative tuberculosis, primary tuberculous complex, tuberculous chancre.

BACKGROUND

Based on World Health Organization (WHO) Global Tuberculosis (TB) Report 2020, Indonesia has the second highest TB burden globally. China, India, and Indonesia account for 45% of TB cases in the world.¹⁻⁵ Extrapulmonary TB (EPTB) includes about 15%–20% of all TB patients.^{5,6} Of the many known kinds of the disease, cutaneous tuberculosis (CTB) is one of the least common, accounting for only 0.5–2% of all EPTB cases. TB is a chronic granulomatous infection caused by *M. tuberculosis complex*, *M. bovis*, and bacillus Calmette-Guérin (BCG). It is renowned for constructing caseating granulomas and an indolent inflammatory reaction, generally in the respiratory system. It can, nonetheless, localize in other various organs. Of the many known kinds of the disease.^{1,2}

CTB can be acquired through different pathways, either by hematogenous or lymphatic dissemination from a pulmonary focus, or by direct inoculation. The clinical presentation of the disease is influenced by the host's immune response before encountering the bacilli.⁷ In individuals who are predisposed, the disease can be acquired by direct inoculation into the skin, resulting in conditions such as tuberculous chancre and tuberculosis verrucosa

cutis. Alternatively, secondary infection can occur from a pre-existing primary focus, and may be caused by contiguous spread (orificial tuberculosis, scrofuloderma), hematogenous dissemination (acute miliary tuberculosis, tuberculous gumma, and lupus vulgaris), or lymphatic spread (lupus vulgaris).^{8,9}

Depending on the amount of bacilli present in the skin, CTB can be categorized into two types. Multibacillary forms, which are easily detected in cutaneous tissue, include tuberculous chancre, scrofuloderma, orificial tuberculosis, acute miliary tuberculosis, and tuberculous gumma. Paucibacillary forms, which have fewer bacilli, include TB verrucosa cutis, tuberculoid, and lupus vulgaris.⁷

The various clinical manifestation of CTB makes the diagnosis difficult.¹⁰ In addition, tissue diagnosis can be difficult because acid-fast bacilli staining and mycobacterial cultures are often found negative.^{5,8} Here we present an unusual case of CTB.

CASE ILLUSTRATION

A 33-year-old woman presented with an erythematous painful solid lump measuring 5 cm x 2 cm on her lower right abdomen that appeared one month ago (Figure 1). She reported no other symptoms, such as

¹Medical Student, Tanjungpura University Teaching Hospital, Tanjungpura University, Pontianak, West Kalimantan, Indonesia;

²Internist, Department of Internal Medicine, Tanjungpura University Teaching Hospital, Pontianak, West Kalimantan, Indonesia.

*Correspondence to:
Mira Delima Asikin;
Tanjungpura University Hospital,
Tanjungpura University, Pontianak,
West Kalimantan, Indonesia;
mirarsuntan@gmail.com

Received : 12 April 2023

Accepted : 19 May 2023

Published : 30 June 2023

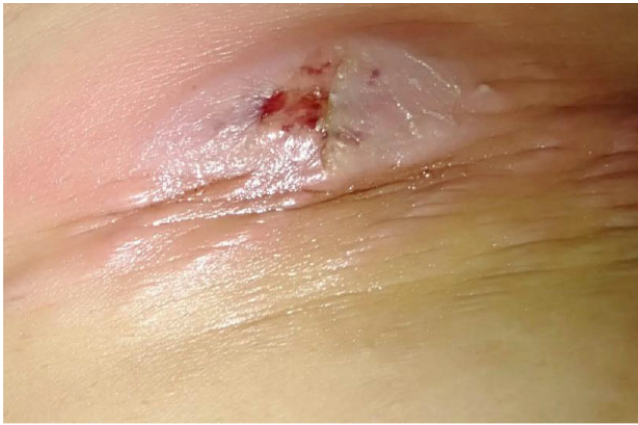

Figure 1. Erythematous painful solid lump on the right lower abdomen.

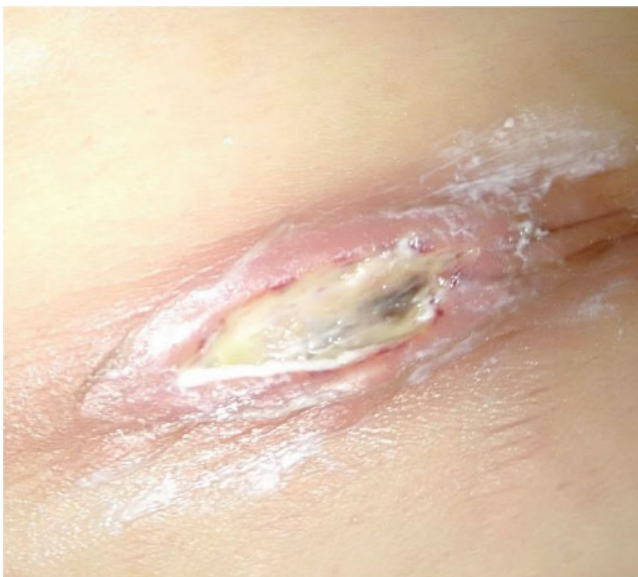

Figure 2. Erythematous painless ulcerative lesion on the right lower abdomen developed from previous skin lesion.

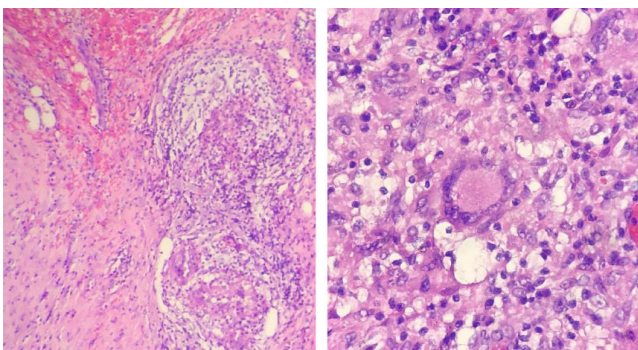


Figure 3. Histopathology of the skin lesion showed fibrous connective tissue that contained granulomas composed by epithelioid histiocytes, lymphocytes, plasma cells, and multinucleated giant cells (Datia Langhans cells).

productive cough, fever, fatigue, sudden weight loss, and night sweats. Vital signs were within normal ranges and no lymphadenopathy was found on physical examination. She has received BCG vaccination in the past and has no history of TB.

The patient reported the skin lesion was not preceded by any trauma. The lesion developed into an erythematous painless ulcer (Figure 2) and was treated with antibiotics and debridement in primary healthcare clinic. There was no improvement and she was referred to the hospital for further treatment. She previously was diagnosed with tumor. The skin lesion was removed and sent to the pathological anatomy department. Histopathology of the skin lesion showed fibrous connective tissue that contained granulomas composed by epithelioid histiocytes, lymphocytes, plasma cells, and multinucleated giant cells (Datia Langhans cells) (Figure 3).

Diagnosis of CTB was made from the anamnesis, physical examination, and further diagnostic examinations. Based on the morphological presentation, the skin lesion appeared to be CTB or tuberculous chancre. The patient was treated with multidrug TB therapy (pyrazinamide, rifampicin, ethambutol, and isoniazid) and vitamin B6.

DISCUSSION

CTB contributes to significant morbidity and mortality despite being seen in only 1.5% of EPTB cases.¹⁰ This is a case of PTC which occurs by direct inoculation of *Mycobacterium tuberculosis* into the skin of previously unsensitized person.

The lesion begins as a hardly descript lesion with red to brown papule or nodule that develops into a shallow, nonpainful, and undermined ulcer with a granulomatous base.¹¹ An abscess can develop at the puncture wounds.¹² The lesion is commonly found on the face or extremities.¹¹ Primary tuberculous chancre develops at the site of traumatized skin within three weeks after inoculation. One or two months after that, painless regional lymphadenopathy may occur.¹⁰

The primary tuberculous complex is categorized as a paucibacillary disease. Mycobacterial cultures, bacterial staining, and smears are often negative. Characteristic features of the primary tuberculous complex include granulomatous tubercles with epithelioid cells, Langerhans giant cells, and mononuclear infiltrates. Diagnostic tools which can help to diagnose this disease are histopathology of the tubercle, isolation of *M. tuberculosis* in cultures of biopsy material, or polymerase chain reaction (PCR).¹⁰

In this case, a histopathology investigation of the skin lesion was done which showed fibrous connective tissue that contained granulomas composed by epithelioid histiocytes, lymphocytes, plasma cells, and multinucleated giant cells (Datia Langhans cells).



Management of the PTC is similar to TB treatment in other organs.¹⁰ This patient was treated with 4-drug fixed-dose combination for 4 months followed by 4-drug fixed-dose combination for 4 months along with vitamin B6.

Diagnosis of CTB is challenging as the skin lesion mimics other conditions and microbiological confirmation is often negative. Although it is reported as less than one percent of all TB cases, it is important for practitioners to consider the infection when faced with a suggestive clinical pictures.¹³

SUMMARY

A case of 33-year-old woman presented with an erythematous painful solid lump has been reported. The lesion developed into an erythematous painless ulcer. Histopathology of the skin lesion showed fibrous connective tissue that contained granulomas. PTC is a rare form of EPTB caused by direct inoculation of *Mycobacterium tuberculosis* into the skin of an unsensitized person. Diagnosis is challenging as microbiological confirmation is often negative, and diagnostic tools such as histopathology, culture, or PCR are needed. Treatment involves a 4-drug fixed-dose combination for 4 months followed by 4 months of continued treatment with vitamin B6. Despite being rare, PTC is important to consider in patients with suggestive clinical pictures of the infection.

CONFLICT OF INTEREST

There is no competing interest regarding the manuscript.

ETHICS CONSIDERATION

This case report has obtained informed consent from the patient as well as the following COPE for publication ethics guidelines.

FUNDING

None.

AUTHOR CONTRIBUTIONS

All authors contribute to the study from selecting a case, evaluating the laboratory results until interpreting the case study through publication.

REFERENCES

- Mahdi E, Alabdan L, Amer S, et al. A case report of tuberculosis in the finger. *Cureus*. 2021;13(2):e14071.
- Dias MF, Bernardes Filho F, Quaresma MV, et al. Update on cutaneous tuberculosis. *An Bras Dermatol*. 2014;89(6):925-938.
- World Health Organization. Who operational handbook on tuberculosis: module 1: prevention: tuberculosis preventive treatment [Internet]. Geneva: World Health Organization; c2021 [cited 2023 Apr 10]. Available from: <https://www.who.int/publications/i/item/9789240002906>.
- World Health Organization. Global Tuberculosis Report 2019 [Internet]. Geneva: World Health Organization; c2021 [cited 2020 Jan 01]. Available from: <https://www.who.int/teams/global-tuberculosis-programme/tb-reports/global-report-2019>.
- Chen Q, Chen W, Hao F. Cutaneous tuberculosis: a great imitator. *Clin Dermatol*. 2019;37(3):192-199.
- Sharma SK, Mohan A, Kohli M. Extrapulmonary tuberculosis. *Expert Rev Respir Med*. 2021;15(7):931-948.
- Khadka P, Koirala S, Thapaliya J. Cutaneous tuberculosis: clinicopathologic arrays and diagnostic challenges. *Dermatol Res Pract*. 2018;2018:7201973.
- van Zyl L, du Plessis J, Viljoen J. Cutaneous tuberculosis overview and current treatment regimens. *Tuberculosis (Edinb)*. 2015;95(6):629-638.
- Santos JB, Figueiredo AR, Ferraz CE, et al. Cutaneous tuberculosis: epidemiologic, etiopathogenic and clinical aspects - Part I. *An Bras Dermatol*. 2014;89(2):219-228.
- Karoney MJ, Kaumbuki EK, Koech MK, et al. Primary cutaneous tuberculosis in a 27-year-old medical intern from needle-stick injury: a case report. *Clin Case Rep*. 2015;3(1):39-42.
- Bleeker-Rovers CP, de Vries HJC. Dermatologic Manifestations of Systemic Infections. In: Cohen J, Powderly WG, Opal SM, eds. *Infectious Diseases*. 4th ed. 2017. Elsevier:113-121.e1.
- Sethuraman G, Ramesh V. Cutaneous tuberculosis in children. *Pediatr Dermatol*. 2013;30(1):7-16.
- Kaul S, Kaur I, Mehta S, et al. Cutaneous tuberculosis. Part I: Pathogenesis, classification, and clinical features. *J Am Acad Dermatol*. 2022; S0190-9622(22)00202-X.



This work is licensed under a
[Creative Commons Attribution 4.0
 International License](https://creativecommons.org/licenses/by/4.0/).